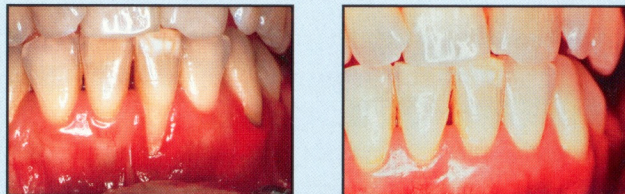


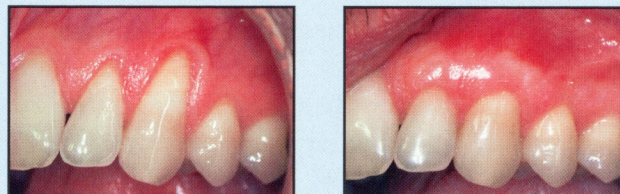Esthetic Periodontal Procedures

Before → After



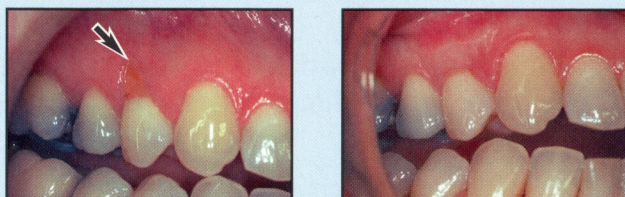
Inflamed, hard-to-clean cleft treated by establishing an attached, keratinized band of gingiva

Before → After



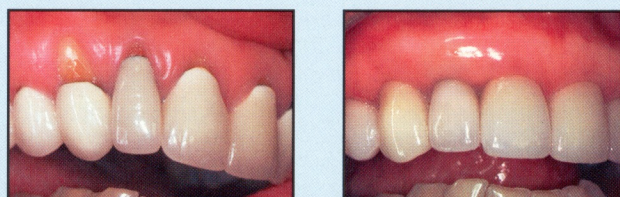
Thin gingiva and advancing recession corrected with an adequate width and thickness of attached gingiva

Before → After



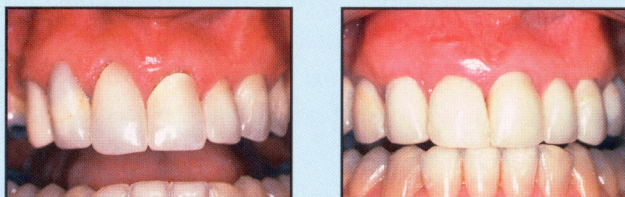
Discolored root surface with decay corrected without the need for a restoration

Before → After



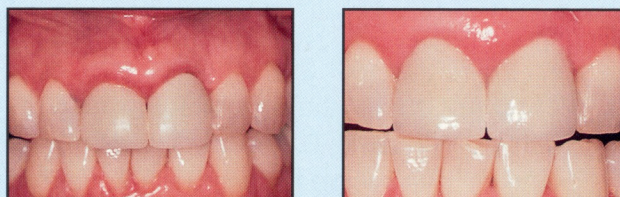
Recession exposing metallic crown margins corrected prior to new restorations

Before → After



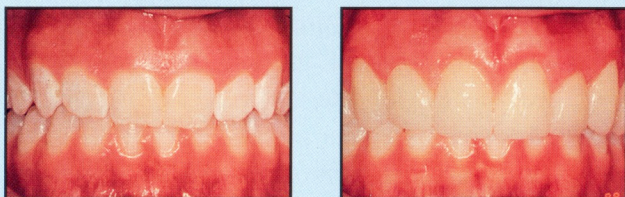
Symmetric gingival frame re-established with corrective tissue grafting

Before → After



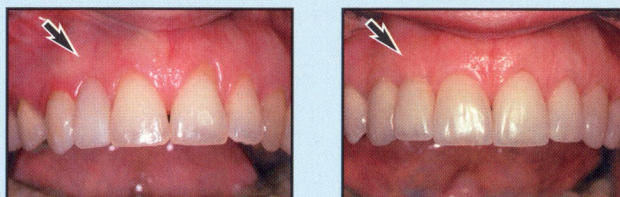
Even levels of gingiva achieved by tissue recontouring

Before → After



Short, square appearance of teeth corrected by gingival sculpting to expose a full smile

Before → After



Flat ridge architecture "plumped" to achieve an attractive emergence profile for the replacement tooth with root-coverage grafting

Potential Benefits of Periodontal Plastic Surgery

- ✓ Greater patient satisfaction
- ✓ An esthetic frame for restorative procedures
- ✓ Excellent cosmetic blending of tissue colors and contours
- ✓ Appropriate tooth length for a fuller, brighter smile
- ✓ Gingival symmetry and harmony
- ✓ An adequate width and thickness of gingiva to prevent further recession
- ✓ More hygienic tissue contours
- ✓ Better emergence profile for pontics
- ✓ Regeneration of lost or deficient tissue
- ✓ Protection of exposed root structure from sensitivity, erosion, and decay
- ✓ Improved restorative access and retention
- ✓ Amalgam tattoo correction
- ✓ Minimal surgical tissue trauma and faster healing
- ✓ Improved predictability of surgical results
- ✓ Enhanced orthodontic treatment results

aesthetic periodontics
implant reconstruction



JULIAN C. LEICHTER, D.M.D., P.A.
LUISA F. RECIO, D.M.D., M.M.Sc.

7000 West Camino Real • Suite 120
Boca Raton, Florida 33433

(561) 391-1800
(888) 81PERIO

www.perioboca.com
info@perioboca.com

Q. What is periodontal plastic surgery?

- A. These are sophisticated surgical procedures to enhance the color, contours, health and comfort of the periodontium. This often involves changing the level of the gingiva to establish the correct amount of tooth exposure. A key objective is a natural cosmetic result with little or no visual evidence that a surgical procedure has been performed.

Q. What are the clinical indications for esthetic periodontal procedures?

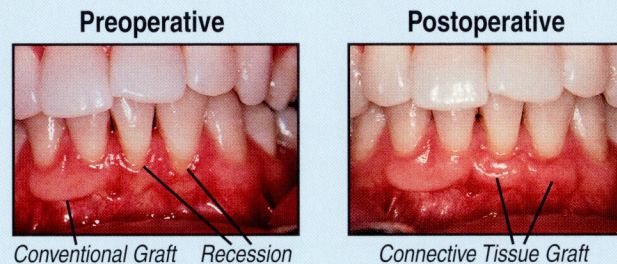
- A. There are typically four applications for periodontal plastic surgery:

- ▶ Clinical crown lengthening to expose more of the teeth for an attractive smile or improved retention and restorative access.
- ▶ Root coverage procedures to protect the roots from erosion, decay and sensitivity while providing an attractive, symmetric appearance.
- ▶ Establishment of a functional zone of attached, keratinized gingiva to prevent recession.
- ▶ Augmentation procedures to reestablish normal tissue contours for a more attractive and hygienic restorative result.

Periodontal plastic surgery can be performed on an outpatient basis with local anesthesia and some form of sedation, if necessary.

Q. What advances have increased the predictability of esthetic periodontal surgery?

- A. Improved root preparation techniques have greatly advanced grafting procedures. Enhanced magnification and illumination provide for superior visual acuity. Smaller instruments, needles and sutures allow for precise surgical margins and minimal tissue trauma. The result of these advances has been shorter healing times, absence of scarring, and an esthetically pleasing blending of gingival contours and color.



The photographs above vividly illustrate the esthetic advances in periodontal plastic surgery. This patient had an existing gingival graft. Notice the superior color and contours of the healed connective tissue graft.

Q. Why are restorative dentists increasingly recommending periodontal plastic surgery for their patients?

- A. In recent years, the demand for cosmetic dentistry has steadily increased. This has been accompanied by higher patient expectations for

an esthetically pleasing final result. Even the finest restorative treatment can be an esthetic disappointment if the periodontal component is not factored into the total treatment plan.

With sophisticated surgical procedures, the periodontist can provide an ideal gingival frame for restorative dentistry. General dentists, prosthodontists and orthodontists are increasingly coordinating treatment with the periodontist to achieve the highest level of health, symmetry and esthetics. Often a collaborative effort can *be* the difference that *makes* the difference in patient satisfaction.

Q. What is the appropriate treatment sequence for esthetic periodontal procedures?

- A. Preprosthetic communication between the periodontist and the restorative dentist is necessary.

Periodontal procedures are usually completed prior to the initiation of restorative treatment. In some cases periodontal surgery is appropriate while the patient has provisional restorations. Periodontal procedures should be completed before impressions are taken for final restorations.

Q. What is the expected longevity of Esthetic Periodontal Surgery?

- A. The long-term stability of periodontal plastic surgery is excellent. As with other periodontal procedures, long-term success is greatly enhanced by regular professional maintenance, effective plaque control and a stable, atraumatic occlusion.